

## Tricuspid Regurgitation After Cardiac Transplantation: An Old Problem Revisited

Raymond Ching-Chiew Wong, MBBS, MRCP,<sup>a</sup> Zuheir Abrahams, MD, PhD,<sup>a</sup> Mazen Hanna, MD,<sup>a</sup> Joseph Pangrace, CMI,<sup>b</sup> Gozalo Gonzalez-Stawinski, MD,<sup>c</sup> Randall Starling, MD, MPH,<sup>a</sup> and David Taylor, MD,<sup>a</sup>

Tricuspid regurgitation (TR) is the most common valvular abnormality after orthotopic heart transplantation (OHT), with a reported incidence of up to 84%, depending on the definition of significant regurgitation and surgical methods of OHT employed. While multiple etiologies are implicated in the development of TR after OHT, endomyocardial biopsy (EMB), performed to detect allograft rejection, is the single most important contributor to significant TR by causing anatomic disruption of the tricuspid valvular structure. Although the clinical course of TR is heterogeneous, hemodynamically significant regurgitation generally leads to progressive right-heart dysfunction and symptoms. In cases refractory to diuretic-based medical therapy, surgical correction of TR has been shown to effectively alleviate the condition and provide symptomatic and organ function improvement. Tricuspid valve repair and replacement are viable surgical options, the application of which often depends on the institution's experience and underlying valve pathology. A non-invasive surveillance technique to detect allograft rejection is on the horizon, and may reduce the number of EMBs performed as well as the procedure-related tissue damage that leads to TR. *J Heart Lung Transplant* 2008;27:247-52. Copyright © 2008 by the International Society for Heart and Lung Transplantation.

Tricuspid regurgitation (TR) is the most common valvular abnormality after orthotopic heart transplantation (OHT). Its reported incidence varies widely at between 19% and 84%,<sup>1-4</sup> depending on the definition of significant TR, when the diagnosis was made, and the surgical technique employed during the transplantation. Other types of valvular dysfunction have also been reported, particularly pulmonary (42%) and mitral (32%) insufficiency.<sup>5</sup> Post-transplant TR is a dynamic disease, and its incidence and severity have been reported to increase with time. Development of significant TR has been associated with increased morbidity and mortality.<sup>6</sup> Although the majority of patients do well with medical therapy, a small proportion of them eventually require surgical intervention. The reference articles, abstracts and reports used in this review were retrieved from PUBMED searches.

From the <sup>a</sup>Section of Heart Failure Transplantation, Department of Cardiovascular Medicine, <sup>b</sup>Center for Medical Art and Photography, and <sup>c</sup>Department of Thoracic and Cardiovascular Surgery, Cleveland Clinic Foundation, Cleveland, Ohio.

Submitted August 15, 2007; revised December 3, 2007; accepted December 17, 2007.

Reprint requests: Raymond Ching-Chiew Wong, MBBS, Department of Cardiovascular Medicine, Cleveland Clinic Foundation, 9500 Euclid Avenue, Cleveland, OH 44195. Telephone: 216-444-3490. Fax: 216-444-7155. E-mail: [hannam@ccf.org](mailto:hannam@ccf.org)

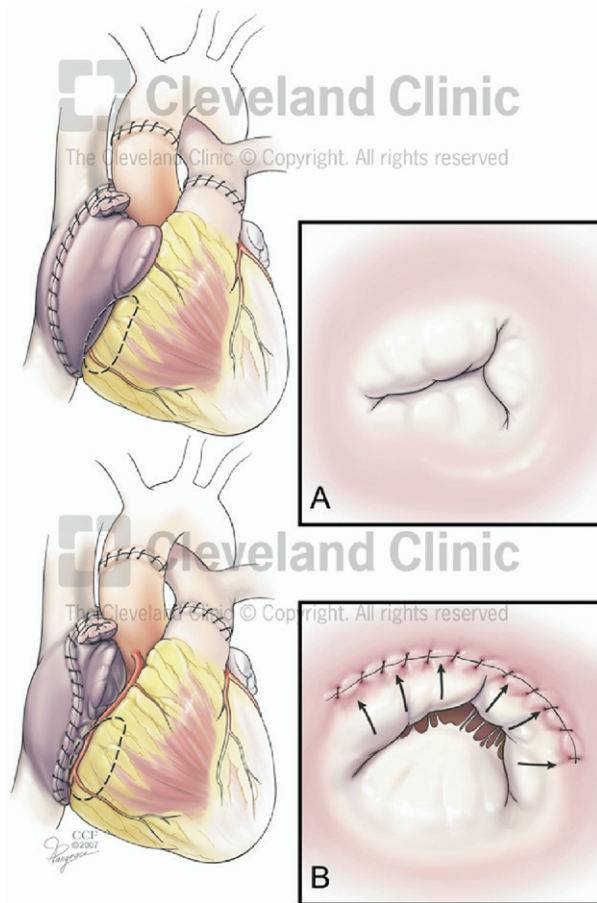
Copyright © 2008 by the International Society for Heart and Lung Transplantation. 1053-2498/08/\$-see front matter. doi:10.1016/j.healun.2007.12.011

### PATHOLOGIC MECHANISM

It is crucial to define and elucidate the pathophysiology behind the development of TR after OHT in order to effectively manage or prevent the problem. The etiologic mechanism of TR can principally be divided into functional or anatomic, with the timing of occurrence being either early or late.

### Functional TR

In functional TR, the regurgitant jet is typically central and caused by geometric distortion of the atrioventricular annular ring and dilation, and malcoaptation of the valve leaflets. Causes include biatrial anastomoses (Figure 1), allograft rejection with right ventricular dysfunction, or mismatch of the donor heart and recipient pericardial cavity. De Simone et al found significant correlation between TR and the ratio of recipient/donor (R/D) right atrium (i.e., atrial size mismatch,  $r = 0.9$ ) and the dimensions of the recipient atrium per se ( $r = 0.89$ ) among patients who had a biatrial cardiac transplantation.<sup>7</sup> Of the 166 patients who underwent OHT with a modified biatrial surgical technique, Dandel et al observed that patients without TR (67%) had a D/R ratio of  $<1$ , whereas those with moderate to severe TR had a D/R ratio of  $>1$ .<sup>8</sup> Further corroborative evidence was provided by Aziz et al, who observed increased occurrence and progressive evolution of TR among 161 patients who underwent the biatrial technique vs 88 who underwent a bicaval approach (41% at 1 month, 52% at 24 months vs 15% at 1 month, 30% at 24 months,



**Figure 1.** A. Artist's rendition of a completed heart transplant using a standard bi-atrial anastomosis technique. It is important to notice the relationship of the AV groove to the right atrial suture line. If the suture line is at a safe distance from the AV groove, adequate coaptation of the leaflets of the tricuspid valve occurs. B. If due to technical mishaps the suture line of the right atrium is placed in too close proximity to the AV groove, the non-tendonous support of the tricuspid valve is distorted resulting in any degree of tricuspid regurgitation.

respectively).<sup>9</sup> This lends strong support to the belief that preservation of atrial and tricuspid annulus geometry is crucial in preventing development of significant TR.

### Other Pathophysiologic Factors

Other factors may have an integral role in adverse atrial remodeling and progressive size enlargement. Pathophysiologic factors, such as allograft rejection beyond Grade 2, pre-operative abnormal transpulmonary gradi-

ent and pulmonary vascular resistance, have been found to independently predict early TR development.<sup>10</sup> Furthermore, the rate of rejection and donor heart weight were found to correlate with higher risk of TR, suggesting physiologic substrates that predispose to abnormal right heart remodeling and after-load, as well as allograft rejection with resultant right ventricular (RV) dysfunction to be important as well.<sup>10,11</sup>

### Anatomic TR

TR may be caused directly by anatomic disruption of the valve apparatus, such as torn leaflet or ruptured chordae tendinae<sup>12</sup>; the excessive leaflet motion is associated with severe prolapse or flail valve. In this respect, endomyocardial biopsy (EMB), performed to detect allograft rejection, is the single most important culprit. The risk of EMB may be variably dependent on the operator's experience, the patient's clinical state, access sites and type of biotome used.<sup>13</sup> Wiklund and colleagues observed 6 (6%) of 96 heart transplant patients who had abrupt appearance of large tricuspid regurgitation. All were directly related to a preceding EMB, with chordal tissue identified histologically in the biopsy samples. The patients subsequently had symptoms of right ventricular failure and 3 patients later underwent tricuspid valvuloplasty.<sup>14</sup>

Huddleston et al reported biopsy-induced TR (defined here as severe and accompanied by flail components of the tricuspid valve) in 12 (7%) of 183 patients who had an average of 16.2 biopsies per patient over mean follow-up period of 4.2 years. Of these, 7 became symptomatic but only 2 underwent corrective valve surgery due to right heart failure refractory to medical therapy.<sup>15</sup> Tucker et al identified 21 (12%) from among their 181 patients who underwent OHT and had flail leaflets or torn chordae tendinae of the tricuspid valve and tricuspid regurgitation. The mean duration from time of transplant was 42 months and the mean number of biopsies was 15.5 per patient. Seven patients (33%) had severe regurgitation.<sup>16</sup> Nguyen et al found that 25 (25%) of 101 patients had severe TR post-transplant. Multivariate analysis identified EMB as the only independent predictor of TR severity. At last follow-up, 60% of patients with >31 EMBs had developed severe TR, compared to 0 with <18 EMBs. Of the 25 patients who had severe TR, 15 (61%) needed high doses of daily

**Table 1.** Association Between Number of Endomyocardial Biopsies (EMBs) and Significant Tricuspid Regurgitation (TR)

	Severe TR (N/total)	No. of EMBs (mean)	Mean follow-up (years)	Symptomatic (N)	Valve surgery (N)
Huddleston et al <sup>15</sup>	12/183	16.2	4.2	7	2
Tucker et al <sup>16</sup>	21/181	15.5	3.5	7	X
Nguyen et al <sup>18</sup>	25/101	31	9.5	15	4
Chan et al <sup>1</sup>	23/336	28	4.5	23	6

The mean number of biopsies is confounded by the duration of follow-up. "X" indicates no data provided.

diuretics and 4 (16%) required tricuspid valve replacement (Table 1).

Two provocative questions remain unanswered: How many biopsies does it take to inflict significant damage to the tricuspid apparatus? How much of this is dependent on the experience of the individual institution? One indisputable fact is that patients who had severe TR and required surgical correction predominantly had chordal destruction from their EMBs and flail tricuspid valve.<sup>17</sup>

### Are All Chordal Disruptions Always Detrimental?

The mere detection of chordae in histologic specimens is not always associated with catastrophic TR. In one study, chordal tissue was detected in 24 (1.9%) of 1,265 biopsies in 206 biopsies. Based on echocardiographic assessment, there was no significant worsening of TR and no major valvular abnormality in any patient after biopsy showing chordal tissue.<sup>19</sup> Similarly, Mielniczuk et al observed no statistical difference in the number of biopsy specimens, number of rejection episodes and overall left or right ventricular systolic function between their patients with and without biopsy specimen evidence of chordal tissue disruption.<sup>4</sup> It is therefore reasonable to conclude that TR causation is multifactorial across a wide spectrum of disease severity.

### PROGRESSION

TR can potentially exert hemodynamic stress on the right ventricle, which then undergoes morphologic remodeling that leads to chamber dilation. This may worsen right-sided atrioventricular coupling geometrically and hemodynamically that in turn causes more TR. Among 336 heart transplant patients appearing for regular echocardiographic follow-up, Chan et al observed that initially 90 (26.8%) and 23 (6.8%) patients had moderate and severe TR, respectively. Mean time from heart transplantation to diagnosis of severe TR was 43 months. At 5 years, 7.8% of surviving patients had severe TR, and at 10 years this reached 14.2%.<sup>1</sup> Williams et al similarly reported a rising incidence of significant TR based on echocardiography performed early at Week 1 and late at  $2.4 \pm 1.3$  years after cardiac transplant, where the incidence rates were 63% and 71% of patients, respectively. In another study, incidence of Grade 3 TR increased from 5% at 1 year to 50% at 4 years after transplantation.<sup>11</sup>

### Early vs Late TR

Few studies have looked at predictors of early vs late TR. One such study reported that development of early TR correlated with allograft rejection of Grade  $\geq 2$ , pre-operatively raised transpulmonary gradient and elevated pulmonary vascular resistance; whereas risk factors for late TR included standard technique, number of

rejections of Grade  $\geq 2$  and total number of EMBs.<sup>10</sup> Further, patients who have had more EMBs may also have had more allograft injury from rejection.

### CLINICAL IMPACT OF TR AFTER CARDIAC TRANSPLANTATION

The majority of patients with moderate to severe TR are asymptomatic. However, adverse clinical consequences have been reported, such as progressive right ventricular dysfunction and failure with debilitating symptoms of dyspnea and dependent edema, use of high-dose diuretics, deteriorating functional status, renal dysfunction and even decreased survival.

### Sub-clinical TR

The effects of sub-clinical TR remain controversial. One report described a benign clinical course for post-transplant patients with less than moderate TR.<sup>20</sup> However, Burgess et al had contrasting observations, as shown by their observation that 9% of patients with apparent TR diagnosed at Week 4 post-transplant had a 90% chance of developing right-heart failure at a mean follow-up of 5 years, leading to an increased incidence of death (28% vs 20%,  $p < 0.001$ ).<sup>21</sup>

### Hemodynamically Significant TR

Progressive RV cavity enlargement, with disproportionate elongation of the mid-minor axis,<sup>22</sup> elevated right-side pressures and more advanced functional class, was associated with more severe TR.<sup>10</sup> Up to 76% of patients with TR had overt right-heart failure in the immediate post-operative period, and this correlated with post-transplant pulmonary hypertension.<sup>5</sup> Lewen et al found that 13 of 14 (93%) patients with moderate to severe TR post-transplant had right ventricular volume overload and higher pulmonary vascular resistance.<sup>2</sup> Williams et al noted higher right atrial pressure (mean 10 vs 6 mm Hg,  $p < 0.05$ ), lower cardiac index (mean 2.0 vs 2.5 liters/min/m<sup>2</sup>,  $p < 0.05$ ) and greater right-side cardiac dimensions in 23 of 72 patients with moderate to severe TR.<sup>23</sup>

With longer follow-up duration, the severity and clinical impact of TR worsens. Among 238 patients who survived  $\geq 1$  year after cardiac transplantation, Aziz et al observed persistent higher mean right atrial pressure, pulmonary artery systolic pressure and RV dimensions among patients with clinical TR. Clinically, 35% of patients complained of fatigue, 61% had chronic fluid congestion, 78% had lower extremity edema, and 29% had liver congestion. Furthermore, renal function and physical capacity were inferior in the same group.<sup>24</sup> TR progression has also been correlated with change in RV diastolic area and tricuspid annulus,<sup>25</sup> and intra-operative TR severity showed a strong correlation with RV dysfunction, peri-operative mortality and odds of late survival.<sup>6,24</sup>

## MANAGEMENT

The mainstay of therapy for symptomatic severe TR is medical use of diuretics. In refractory cases, surgical intervention becomes indicated. This involves either application of tricuspid annuloplasty or tricuspid valve repair or replacement, depending on the anatomic abnormality of the tricuspid apparatus. In tricuspid annular dilation, application of the annuloplasty ring may be sufficient to reduce the effective regurgitant orifice. In contrast, surgical repair or replacement is required with leaflet or chordal damage to restore a functional atrioventricular valve apparatus in the right heart. There have been multiple reports on the feasibility, clinical efficacy and safety of surgical treatment of TR post-transplant.

Overall, various reports have cited tricuspid valve replacement (TVR) incidence rates of between 4% and 6% in the post-transplant population, with a mean lag time of 12 to 21 months.<sup>6,26,27</sup> In another series, however, only 5 (0.95%) of 526 of cardiac transplant patients were later subject to tricuspid valve surgery due to severe TR.<sup>28</sup> If replacement is performed, the best results are achieved before right ventricular function deteriorates due to severe TR.<sup>29</sup> Most patients have shown a reduction in their furosemide dose and lower serum creatinine levels, as well as significantly improved albumin and total bilirubin values, implying relief of hepatic congestion.<sup>1,27</sup>

### Valve Repair or Replacement?

Currently available data support surgical correction of severe TR as the most effective way of managing intractable right-heart failure and improving the quality of life. The unresolved issue, however, is whether valve repair or replacement should be recommended, as there has been no randomized, prospective trial to address this option. Alharethi et al reported from the Utah Transplantation Affiliated Hospitals (UTAH) Cardiac Transplant Program database 17 patients who had 16 TVR and 2 TV repair procedures performed. One patient died post-operatively due to cardiogenic shock and another died 8 months after TVR due to progressive right-heart failure. After a mean of 33 months, improvement in heart failure symptoms was reported in 12 cases. Central venous pressure (CVP) decreased from 17.8 mm Hg to 11.0 mm Hg ( $p = 0.013$ ). In addition, furosemide dose decreased significantly from 48 mg/day to 27 mg/day ( $p = 0.009$ ). However, cardiac output or renal function remained unchanged.<sup>17</sup> Because there were only two repairs, a meaningful comparison with valve replacement was not described. Wahlers et al reported superior outcome among 8 patients with TVR compared to 4 with valve repair, in terms of decreased TR and better ventricular remodeling, but the sample

size was again insufficient to draw any definitive conclusion. In another series, Filsoufi et al reported 8 patients with symptomatic severe TR who underwent TV surgery at a mean 21 months after OHT. Two had annuloplasty only, 4 had valve repair and annuloplasty, and 2 had replacement. The outcome for repairs was sub-optimal, as 3 of the 6 primary repairs failed and required replacement with a bio-prosthesis at 8 days, 14 days and 4 years, respectively. Overall, no instance of failure occurred in any of the five bioprosthetic valves placed at the primary operation or after failed tricuspid repair/pulmonary allograft at a mean 55 months of follow-up.<sup>26</sup>

It can be concluded that the existing data support the belief that valve repair with a remodeling annuloplasty should be strongly considered in cases of dilated tricuspid annulus; however, a bio-prosthetic valve replacement is preferred in leaflet prolapse and biopsy-induced chordal injury.<sup>26</sup> The latter has the advantage of durability, allowing future EMBs with a minimally increased risk of structural damage, as well as not requiring long-term anti-coagulation.

## PREVENTION

### Prophylactic Donor Heart Tricuspid Valve Annuloplasty

To avoid the development of significant TR to the donor heart, several preventive measures appear to be effective. Performing prophylactic tricuspid valve annuloplasty (TVA) on the donor heart at the time of transplantation has been shown to reduce TR immediately post-transplant as well as on long-term follow-up. Jevanadam et al randomized 30 patients each into standard bicaval with or without concomitant DeVega TVA. They reported no difference between groups in long-term survival at 5-year follow-up, but there was a statistical advantage in the TVA group with regard to peri-operative cardiac mortality (7 of 30 vs 3 of 30), average amount of tricuspid regurgitation (1.5 vs 0.5), percentage of patients with TR  $\geq 2^+$  (34% vs 0%), serum creatinine (2.9 vs 1.8 mg/dl) and difference in serum creatinine over baseline (2.0 vs 0.7 mg/dl).<sup>30</sup> Brown et al described 25 consecutive patients who underwent biatrial cardiac transplantation with a Cabrol modification, all of whom received a donor heart tricuspid annuloplasty (TA) with either a DeVega or Ring technique. There was no reported hospital death, and patients undergoing transplantation without TA had a higher TR score; moderate or severe TR was present in 8 of 25 patients without TA compared with 0 of 25 patients with TA ( $p = 0.004$ ).<sup>31</sup>

### Longer Biotome Sheath

The use of a longer sheath at the time of EMB allows the biotome to advance beyond the tricuspid valve without physical contact. This has been shown to dramatically

reduce both the prevalence of flail tricuspid leaflet (41% to 6%,  $p < 0.0001$ ) and mean grade of TR (2 to 1,  $p < 0.0001$ ) were reduced after use of a 45-cm sheath.<sup>23</sup>

### Non-invasive Detection of Rejection in Cardiac Allograft Recipients

Endomyocardial biopsy is the “gold standard” of rejection surveillance after cardiac transplantation.<sup>32</sup> However, it is invasive, causes morbidity, and is subject to sampling error and inter-observer variability.<sup>33</sup> Alternative non-invasive monitoring therapies have been tested and one such technology is the gene expression profiling test, also known as the AlloMap test. It uses real-time polymerase chain reaction technology to generate scores based on the expression of 20 genes.<sup>34,35</sup> AlloMap scores have been shown to discriminate between quiescence and moderate/severe acute cellular rejection in the CARGO (Cardiac Allograft Rejection Gene Expression Observational) study. A recently published study also demonstrated that transplant vasculopathy was associated with a higher AlloMap score.<sup>36</sup>

### Intramyocardial Electrocardiography

Daily intramyocardial electrocardiography (IMEG) observation as an alternative regimen of rejection monitoring has been utilized by Yankah et al, who performed EMBs with a 45-cm-long sheath biptome only in cases with doubtful IMEG and echocardiographic data and at times of annual routine heart catheterization. The group reported that only 16 (2.5%) of 647 patients with severe TR required surgical correction.<sup>37</sup> After the application of IMEG, the group performed only 4.8 biopsies per patient per year. This, in conjunction with the long biptome sheath used, this was suggested to account for the lower-than-expected rate of severe TR.

### Echocardiography

The following echocardiographically detected anomalies have been found to correlate with post-transplant rejection episodes: decreased tissue Doppler velocity, ejection fraction and stroke volume; increased pericardial effusion and posterior wall thickness; shortened isovolumic relaxation time; mitral inflow E/A ratio  $>1.7$ ; inferior vena cava diameter; and duration of pulmonary vein atrial reversal.<sup>38,39</sup>

### CONCLUSIONS

Tricuspid valve regurgitation of the donor heart after cardiac transplantation is a real-world problem. A significant minority of patients develop debilitating clinical symptoms of right-heart failure that necessitate tricuspid valve surgery. Although the condition may be multifactorial in etiology, an endomyocardial biopsy showing chordal damage is the single most prominent

reason for severe tricuspid regurgitation. Tricuspid valve repair and replacement surgery is indicated when right-heart failure becomes refractory to conservative medical treatment. Although proven to be safe, these surgical procedures nevertheless confer higher morbidity and mortality rates in post-transplant patients. Methods that facilitate rejection surveillance, such as IMEG and GEP testing, may become important adjuncts and allow for reduced frequency of endomyocardial biopsies in the near future.

### REFERENCES

1. Chan MC, Giannetti N, Kato T, et al. Severe tricuspid regurgitation after heart transplantation. *J Heart Lung Transplant* 2001;20:709–17.
2. Lewen MK, Bryg RJ, Miller LW, Williams GA, Labovitz AJ. Tricuspid regurgitation by Doppler echocardiography after orthotopic cardiac transplantation. *Am J Cardiol* 1987;59:1371–4.
3. De Simone R, Lange R, Sack RU, Mehmanesh H, Hagl S. Atrioventricular valve insufficiency and atrial geometry after orthotopic heart transplantation. *Ann Thorac Surg* 1995;60:1686–93.
4. Mielniczuk L, Haddad H, Davies RA, Veinot JP. Tricuspid valve chordal tissue in endomyocardial biopsy specimens of patients with significant tricuspid regurgitation. *J Heart Lung Transplant* 2005;24:1586–90.
5. Cladellas M, Oriol A, Caralps JM. Quantitative assessment of valvular function after cardiac transplantation by pulsed Doppler echocardiography. *Am J Cardiol* 1994;73:1197–201.
6. Anderson CA, Shernan SK, Leacche M, et al. Severity of intraoperative tricuspid regurgitation predicts poor late survival following cardiac transplantation. *Ann Thorac Surg* 2004;78:1635–42.
7. De Simone R, Lange R, Sack FU, Mehmanesh H, Hagl S. Atrioventricular valve insufficiency and atrial geometry in orthotopic heart transplantation. *Cardiologia (Rome, Italy)* 1994;39:325–34.
8. Dandel M, Hummel M, Loebe M, et al. Right atrial geometry and tricuspid regurgitation after orthotopic heart transplantation: benefits of a modified biatrial surgical technique. *J Heart Lung Transplant* 2001;20:246–7.
9. Aziz T, Burgess M, Khafagy R, et al. Bicaval and standard techniques in orthotopic heart transplantation: medium-term experience in cardiac performance and survival. *J Thorac Cardiovasc Surg* 1999;118:115–22.
10. Aziz TM, Burgess MI, Rahman AN, et al. Risk factors for tricuspid valve regurgitation after orthotopic heart transplantation. *Ann Thorac Surg* 1999;68:1247–51.
11. Hausen B, Albes JM, Rohde R, et al. Tricuspid valve regurgitation attributable to endomyocardial biopsies and rejection in heart transplantation. *Ann Thorac Surg* 1995;59:1134–40.
12. Braverman AC, Copen SE, Mudge GH, Lee RT. Ruptured chordae tendineae of the tricuspid valve as a complication of endomyocardial biopsy in heart transplant patients. *Am J Cardiol* 1990;66:111–3.
13. Cooper LT, Baughman KL, Feldman AM, et al. The role of endomyocardial biopsy in the management of cardiovascular disease: a scientific statement from the American Heart Association, the American College of Cardiology, and the European Society of Cardiology endorsed by the Heart Failure Society of America and the Heart Failure Association of the European Society of Cardiology. *Eur Heart J* 2007.
14. Wiklund L, Caidahl K, Kjellstrom C, et al. Tricuspid valve insufficiency as a complication of endomyocardial biopsy. *Transplant Int* 1992;5(suppl 1):S255–8.

15. Huddleston CB, Rosenbloom M, Goldstein JA, Pasque MK. Biopsy-induced tricuspid regurgitation after cardiac transplantation. *Ann Thorac Surg* 1994;57:832-6.
16. Tucker PA II, Jin BS, Gaos CM, et al. Flail tricuspid leaflet after multiple biopsies following orthotopic heart transplantation: echocardiographic and hemodynamic correlation. *J Heart Lung Transplant* 1994;13:466-72.
17. Alharethi R, Bader F, Kfoury AG, et al. Tricuspid valve replacement after cardiac transplantation. *J Heart Lung Transplant* 2006;25:48-52.
18. Nguyen V, Cantarovich M, Cecere R, Giannetti N. Tricuspid regurgitation after cardiac transplantation: how many biopsies are too many? *J Heart Lung Transplant* 2005;24(suppl):S227-31.
19. Wiklund L, Suurkula MB, Kjellstrom C, Berglin E. Chordal tissue in endomyocardial biopsies. *Scand J Thorac Cardiovasc Surg* 1994;28:13-8.
20. Rees AP, Milani RV, Lavie CJ, Smart FW, Ventura HO. Valvular regurgitation and right-sided cardiac pressures in heart transplant recipients by complete Doppler and color flow evaluation. *Chest* 1993;104:82-7.
21. Burgess MI, Aziz T, Yonan N. Clinical relevance of subclinical tricuspid regurgitation after orthotopic cardiac transplantation. *J Am Soc Echocardiogr* 1999;12:164.
22. Reynertson SI, Kundur R, Mullen GM, et al. Asymmetry of right ventricular enlargement in response to tricuspid regurgitation. *Circulation* 1999;100:465-7.
23. Williams MJ, Lee MY, DiSalvo TG, et al. Biopsy-induced flail tricuspid leaflet and tricuspid regurgitation following orthotopic cardiac transplantation. *Am J Cardiol* 1996;77:1339-44.
24. Aziz TM, Saad RA, Burgess MI, Campbell CS, Yonan NA. Clinical significance of tricuspid valve dysfunction after orthotopic heart transplantation. *J Heart Lung Transplant* 2002;21:1101-8.
25. Williams MJ, Lee MY, DiSalvo TG, et al. Tricuspid regurgitation and right heart dimensions at early and late follow-up after orthotopic cardiac transplantation. *Echocardiography* 1997;14:111-8.
26. Filsoufi F, Salzberg SP, Anderson CA, et al. Optimal surgical management of severe tricuspid regurgitation in cardiac transplant patients. *J Heart Lung Transplant* 2006;25:289-93.
27. Raghavan R, Cecere R, Cantarovich M, Giannetti N. Tricuspid valve replacement after cardiac transplantation. *Clin Transplant* 2006;20:673-6.
28. Stahl RD, Karwande SV, Olsen SL, et al. Tricuspid valve dysfunction in the transplanted heart. *Ann Thorac Surg* 1995;59:477-80.
29. Wahlers T, Albes J, Pethig K, et al. Valve reconstruction or replacement for long-term biopsy-induced tricuspid regurgitation following heart transplantation. *Transplant Int* 1996;9(suppl 1):S247-8.
30. Jeevanandam V, Russell H, Mather P, et al. Donor tricuspid annuloplasty during orthotopic heart transplantation: long-term results of a prospective controlled study. *Ann Thorac Surg* 2006;82:2089-95.
31. Brown NE, Muehlebach GF, Jones P, et al. Tricuspid annuloplasty significantly reduces early tricuspid regurgitation after biatrial heart transplantation. *J Heart Lung Transplant* 2004;23:1160-2.
32. Stewart S, Winters GL, Fishbein MC, et al. Revision of the 1990 working formulation for the standardization of nomenclature in the diagnosis of heart rejection. *J Heart Lung Transplant* 2005;24:1710-20.
33. Navia JL, Atik FA, Vega PR, et al. Tricuspid valve repair for biopsy-induced regurgitation in a heart transplant recipient. *J Heart Valve Dis* 2005;14:264-7.
34. Deng MC, Eisen HJ, Mehra MR, et al. Noninvasive discrimination of rejection in cardiac allograft recipients using gene expression profiling. *Am J Transplant* 2006;6:150-60.
35. Starling RC, Pham M, Valantine H, et al. Molecular testing in the management of cardiac transplant recipients: initial clinical experience. *J Heart Lung Transplant* 2006;25:1389-95.
36. Yamani MH, Taylor DO, Rodriguez ER, et al. Transplant vasculopathy is associated with increased AlloMap gene expression score. *J Heart Lung Transplant* 2007;26:403-6.
37. Yankah AC, Musci M, Weng Y, et al. Tricuspid valve dysfunction and surgery after orthotopic cardiac transplantation. *Eur J Cardiothorac Surg* 2000;17:343-8.
38. Sade LE, Sezgin A, Ulucam M, et al. Evaluation of the potential role of echocardiography in the detection of allograft rejection in heart transplant recipients. *Transplant Proc* 2006;38:636-8.
39. Sun JP, Abdalla IA, Asher CR, et al. Non-invasive evaluation of orthotopic heart transplant rejection by echocardiography. *J Heart Lung Transplant* 2005;24:160-5.